ISSN 2612-7601
Vol. 2 - n. 2 - 2019

ADVANCES IN UROLOGICAL DIAGNOSIS AND IMAGING

EDITOR IN CHIEF
Andrea B. Galosi
CO-EDITOR
Pasquale Martino

OFFICIAL JOURNAL of

S.I.E.U.N.

Italian Society of Integrated Diagnostic in Urology, Andrology, Nephrology

SAVE THE DATE

XXII Congresso Nazionale

ANCONA SIEUN 2020

SOCIETÀ ITALIANA DI DIAGNOSTICA INTEGRATA IN UROLOGIA, ANDROLOGIA, NEFROLOGIA

S.I.E.U.N.

PRESIDENTE S.I.E.U.N.

- Andrea Benedetto Galosi

PRESIDENTI DEL CONGRESSO

- Lucio Dell'Atti
- Gian Marco Giuseppetti
- Andrea Ranghino

TOPICS

- CORSO SIU-SIRM RM PROSTATA BIOPSIA
- CORSO ECOGRAFIA ANDROLOGICA (SIA)
- CORSO ECOGRAFIA PRATICA BEDSIDE (SIUT)
- CORSO ECOGRAFIA NEFROLOGICA (SIN)
- NOVITÀ, LIMITI E VANTAGGI DELLA BIOPSIA FUSION VS MAPPING
- EUROPEAN SOCIETY UROLOGICAL IMAGING
- LINEE GUIDA BIOPSIA PROSTATICA 2020
- DIAGNOSTICA INTEGRATA NELLA ALTA VIA ESCRETRICE (DA RIRS A IMAGING)
- IMAGING E TERAPIA ANDROLOGICA
- NEOPLASIE DEL TESTICOLO
- CALCOLOSI
- TERAPIA FOCALE CA. PROSTATA
- SEMI LIVE SURGERY

SEGRETERIA ORGANIZZATIVA

Congressare by Promise Group
Via Ghino Valenti, 2 Ancona
t. 071202123
congressare@promisegroup.it
www.congressare.it

Ancona, 28-30 Aprile 2020
Mole Vanvitelliana

DEAD LINE INVIO ABSTRACT & VIDEO: 31 GENNAIO 2020
I LAVORI ACCETTATI VERRANNO PUBBLICATI SULLA RIVISTA:
Advances in Urological Diagnosis and Imaging - AUDI

ADVANCES IN UROLOGICAL DIAGNOSIS AND IMAGING

Official Journal of S.I.E.U.N.

EDITOR in CHIEF
Andrea B. Galosi, Ancona (IT)

CO-EDITOR
Pasquale Martino, Bari (IT)

ASSISTANT EDITOR
Lucio Dell'Atti, Ancona (IT)

EDITORIAL BOARD

Urology
Ahmed Hashim, London (GB), Artibani Walter, Verona (IT)
Battaglia Michele, Bari (IT), Bucci Stefano, Trieste (IT)
Carini Marco, Firenze (IT), Carrieri Giuseppe, Foggia (IT)
De Nunzio Cosimo, Roma (IT), Fandella Andrea, Treviso (IT)
Ficarra Vincenzo, Messina (IT), Finazzi Agrò Enrico, Roma (IT)
Franzese Corrado, Nola (IT), Gunelli Roberta, Forlì (IT)
Kastner Christof, Cambridge (GB), Lapini Alberto, Firenze (IT)
Miano Roberto, Roma (IT), Mirone Vincenzo, Napoli (IT)
Montorsi Francesco, Milano (IT), Morgia Giuseppe, Catania (IT)
Muller Stefan, Bonn (GE), Palazzo Silvano, Bari (IT)
Pavlovich Christian, Baltimore, Maryland (USA)
Pepe Pietro, Catania (IT), Rocco Bernardo, Modena (IT)
Salomon George, Hamburg (GE)
Schiavina Riccardo, Bologna (IT), Scattoni Vincenzo, Milano (IT)
Volpe Alessandro, Novara (IT), Waltz Joachen, Marseille (FR)

Andrology
Bettocchi Carlo, Bari (IT), Bitelli Marco, Roma (IT)
Cai Tommaso, Trento (IT), Cormio Luigi, Foggia (IT)
Fusco Ferdinando, Napoli (IT), Gontero Paolo, Torino (IT)
Liguori Giovanni, Trieste (IT), Lotti Francesco, Firenze (IT)
Pizzocaro Alessandro, Milano (IT), Trombetta Carlo, Trieste (IT)

Nephrology
Boscutti Giuliano, Trieste (IT), D'Amelio Alessandro, Lecce (IT),
Fiorini Fulvio, Rovigo (IT), Gesualdo Loreto, Bari (IT),
Granata Antonio, Agrigento (IT), Ranghino Andrea, Ancona (IT)

Radiology
Barozzi Libero, Bologna (IT), Bertolotto Michele, Trieste (IT)
Giuseppetti Gian Marco, Ancona (IT),
Giovagnoni Andrea, Ancona (IT), Valentino Massimo, Tolmezzo (IT)

Pathology
Beltran Antonio Lopez, Lisbon (PT)
Fiorentino Michelangelo, Bologna (IT)
Liang Cheng, Indianapolis (USA),
Montironi Rodolfo, Ancona (IT)

Bio-Medical Engineering
Wijkstra Hessel, Eindhoven (NL)

General Information

AIMS and SCOPE

"Advances in Urological Diagnosis and Imaging" (AUDI) has the purpose of promoting, sharing and favorite technical-scientific research on echography and imaging diagnosis, in diagnostic and terapeutical field of Urology, Andrology and Nefrology. AUDI publishes original articles, reviews, case reports, position papers, guidelines, editorials, abstracts and meeting proceedings.

AUDI is Open Access at www.issuu.com

Why Open Access? Because it shares science at your finger tips with no payment. It is a new approach to medical literature, offering accessible information to all readers, becoming a fundamental tool, improving innovation, efficiency and interaction among scientists.

COPYRIGHT

Papers are accepted for publication with the understanding that no substantial part has been, or will be published elsewhere. By submitting a manuscript, the authors agree that the copyright is transferred to the publisher if and when the article is accepted for publication. The copyright covers the exclusive rights to reproduce and distribute the article, including reprints, photographic reproduction and translation. No part of this publication may be reproduced, stored in a retrieval system, or transmitted in any form or by any means, electronic, mechanical, photocopying, recording or otherwise, without the prior written permission of the Publisher.

BUSINESS INFORMATION

Price for single printed issue: Euro 20,00
Annual subscription rate for the printed version (3 issues) is Euro 52,00.
Subscription orders should be sent to:
Edizioni Scripta Manent s.n.c.
Via Melchiorre Gioia 41/A - 20124 Milano, Italy
Tel. +39 0270608060 - e-mail: info@edizioniscriptamanent.eu
Payments should be made by Bank transfer to:
Edizioni Scripta Manent s.n.c.
Unicredit Milano
IBAN: IT 23 K 02008 01749 000100472830

ADVERTISING

For details on media opportunities within this journal please contact
Mrs. Donatella Tedeschi, MD at **+39 0270608060**

Contents

31 **Multiparametric MRI/TRUS fusion prostate biopsy: The transperineal approach**
Pietro Pepe, Andrea Fandella, Andrea Benedetto Galosi

35 **How much for the fusion biopsy. Cost analysis of the prostate ultrasound guided biopsy in the era of multiparametric MRI, preliminary results**
Andrea Fandella, Pietro Pepe

40 **Association between urological and cardiovascular malformations in non-identical twins**
Clelia Tripaldi, Marcello Campagna, Ottavio Colamonico, Alessandro Mastrorosa, Pasquale Martino, Silvano Palazzo

43 **Ultrasound in the management of a non sexual-related penile blunt trauma**
Andrea Fabiani, Luca Lepri, Emanuele Principi, Cristiana Biondi, Emanuele Rossi, Lucilla Servi

47 **Complete regression of metastatic bladder carcinoma following chemotherapy**
Alessia Cimadamore, Matteo Tallè, Paola Fulvi, Andrea Benedetti Galosi, Rodolfo Montironi

51 **Contemporary use of pelvic drain after robot assisted radical prostatectomy: is always mandatory?**
Simone Scarcella, Lucio Dell'Atti, Andrea BenedettoGalosi

53 **Glycerophosphoinositol rectal suppositories: rationale of application in male with chronic pelvic pain syndrome**
Lorenzo Montesi, Erika Palagonia, Angelo Antezza, Carmine Franzese, Simone Scarcella, Andrea Benedetto Galosi

Edizioni Scripta Manent s.n.c.
Via Melchiorre Gioia 41/A - 20124 Milano, Italy
Tel. +39 0270608060
Registrazione: Tribunale di Milano n. 19 del 17/01/2018
e-mail: info@edizioniscriptamanent.eu
web: www.edizioniscriptamanent.eu

SCRIPTA MANENT EDIZIONI Ubi Consistam

Direttore Responsabile: *Pietro Cazzola*
Direzione Marketing e PR: *Donatella Tedeschi*
Comunicazione e Media: *Ruben Cazzola*
Grafica e Impaginazione: *Cinzia Levati*
Affari Legali: *Avv. Loredana Talia (MI)*
Stampa: *Lalitotipo, Settimo Milanese (MI)*

The total or partial reproduction, by any means, is forbidden without the written authorization of the Publisher.
The Publisher is not liable for the opinion expressed by the Authors of the articles and for images used by them.

ORIGINAL PAPER

Multiparametric MRI/TRUS fusion prostate biopsy: The transperineal approach

Pietro Pepe[1], Andrea Fandella[2], Andrea Benedetto Galosi[3]

[1] Urology Unit – Prostate Cancer Unit - Cannizzaro Hospital, Catania, Italy;
[2] Urology Unit– Giovanni XXIII Clinic, Monastier di Treviso, Italy;
[3] Department of Urology, Polytechnic University of Marche, Ancona, Italy.

SUMMARY

***Objectives**: To evaluate the detection rate for clinically significant prostate cancer (csPCa) of transperineal multiparametric MRI/TRUS (magnetic resonance imaging/transrectal ultrasound) fusion targeted biopsy (TPBx).*
***Materials and Methods.** We previously reported our experience in the detection for csPCa (Gleason score > 6 and/or more than two positive cores and or GPC > 50%) performing TPBx; from 1032 men (median age 63 years) with negative digital rectal examination and previous negative biopsy underwent repeat transperineal saturation biopsy (SPBx; reference test) for the suspicion of cancer. All the patients underwent pelvic mpMRI and in the lesions characterized by a PI-RADS score > 3 (524 cases) a TPBx (four cores) was added to SPBx.*
***Results**: None had significant complications (Clavien-Dindo grade I) from prostate biopsy that needed hospital admission; a T1c PCa was found in 372/1032 (36%) patients and 272 (73.1%) of them were classified as csPCa. The detection rate for overall cancers vs csPCa using SPBx vs TPBx PIRADS > 3 vs TPBx PIRADS > 4 was equal to 90.3 and 95.6% vs 72% and 83.8% vs 48.4 and 60.3%, respectively; SPBx missed 12 (4.5%) suggestive as being csPCa vs 44 (16.2%) and 108 (39.7%) missed by TPBx PI-RADS > 3 and TPBx PI-RADS > 4, respectively. In detail, 40/228 (17.5%) csPCa were diagnosed in the anterior zone of the gland by TPBx.*
***Conclusions**: Although mpMRI is mandatory to improve the accuracy of prostate biopsy in the diagnosis of csPCa, still today, the systematic biopsy should be performed, anyway, in addition to targeted cores (PIRADS score > 3) or alone (negative mpMRI) in the presence of clinical parameters suspicious for cancer; in this respect, the transperineal approach reset the risk of sepsis and improve the diagnosis of csPCa located in the anterior zone of the gland.*

***KEY WORDS:** Prostate cancer; multiparametric MRI; transrectal fusion biopsy; transperineal fusion biopsy; saturation prostate biopsy.*

INTRODUCTION

Prostate cancer (PCa) is the most frequent tumor diagnosed in older men with more than 1 million biopsies a year performed in the United States (1). The transrectal prostate biopsy approach is associated with an increased risk of infection with an estimated hospital admission and sepsis equal to 2.5 (3) and 3.5% (4), respectively; in addition, the rate of overdiagnosis in men enrolled in screening protocols is equal to 50% of the cases (2). Therefore, the main goal is to reduce the number of unnecessary biopsies and diagnose only clinically significant PCa. In this respect, multiparametric magnetic resonance imaging (mpMRI) combined with TRUS (transrectal ultrasound) fusion targeted biopsy has improved the accuracy of standard biopsy schemes in detecting clinically significant prostate cancer (csPCa), especially, in case of a repeat biopsy (5-7) and in the reevaluation of men enrolled in active surveillance (AS) programs (8-10). Although the accuracy of mpMRI/fusion targeted biopsy has been evaluated in a lot of series, very few papers have compared the detection rate for PCa or/and complications of the different MRI/TRUS fusion platforms and/or approaches in the same population (11-14); in this respect, the standard transperineal biopsy in comparison with the transrectal procedure has demostrated a higher accuracy in diagnosing PCa located in the anterior zone of the gland (15) resetting the risk of sepsis (16).
In this report, the advantages of the transperineal fusion targeted biopsy (TPBx) in the diagnosis of csPCa (17) have been evaluated.

MATERIALS AND METHODS

We previously reported our experience in the detection for csPCa performing TPBx (18); from January 2011 to Febraury 2018 1032 men (median age 63 years) with negative digital rectal examination and previous negative biopsy underwent repeat transperineal saturation biopsy (SPBx; reference test) for the suspicion of cancer (increasing or persistently elevated PSA values). All the patients underwent pelvic mpMRI; SPBx (median of 30 cores; range: 28-34 cores) was performed transperineally using a GE Logiq P6 ecograph (General Electric; Milwaukee, WI, USA) supplied with a bi-planar trans-rectal probe (5-7.5

MHz) using a tru-cut 18 gauge needle (Bard; Covington, GA, USA) under sedation and antibiotic prophylaxis (one tablet daily of levofloxacin 500 mg for 3 days) (18). All mpMRI examinations were performed using a 3.0 Tesla scanner, (ACHIEVA 3T; Philips Healthcare Best, the Netherlands) equipped with surface 16 channels phased-array coil placed around the pelvic area with the patient in the supine position; multi-planar turbo spin-echo T2-weighted, axial diffusion weighted imaging, axial dynamic contrast enhanced MRI were performed for each patient. The mpMRI lesions characterized by a PI-RADS score > 3 were considered suspicious for cancer; moreover, two radiologists blinded to pre-imaging clinical parameters evaluated the mpMRI data separately and independently. In the presence of mpMRI lesions suggestive of cancer (524 cases) a fusion targeted biopsy (four cores) was added to SPBx: cognitive transperineal fusion biopsy in 229 cases, mpMRI TRUS fusion biopsy (GE Logiq E9, General Electric; Milwaukee, WI, USA) in 169 cases and transperineal fusion guided-biopsies (Hitachi 70 Arietta ecograph, Chiba, Japan) in 126 cases, respectively (7); the targeted biopsies of the anterior zone lesions were always performed transperineally. The GE Logiq E9 and Hitachi Arietta 70 platforms allowed processing of a software-based rigid registration of pelvic mpMRI and TRUS (end-fire probe and biplanar probe, respectively) by the use of a fusion device; moreover, an electromagnetic tracking system showed the needle localization. The data were collected following the START criteria (13).

Results

The median total PSA and prostate weight was 8.6 ng/ml (range: 3.5-46 ng/ml) and 57 grams (range: 20-135 grams), respectively; a mpMRI PI-RADS score > 3 vs > 4 was found in 524/1032 (50.7%) vs 272/1032 (26.3%) cases, respectively (18). None had significant complications (Clavien-Dindo grade I) from prostate biopsy that needed hospital admission; moreover, the mpMRI procedure was well tolerated and successfully performed in all cases (men with claustrophobia, cardiac pacemaker and hip replacement were not included in the study). A T1c PCa was found in 372/1032 (36%) patients and 272 (73.1%) of them were classified as csPCa: a Gleason score 3 + 4 vs 4 + 3 vs 4 + 4 vs 4 + 5 was found in 112 (41.1%) vs 60 (22.1%) vs 50 (18.4%) vs 50 (18.4%) cases. The Gleason score was directly correlated with PI-RADS score; moreover, the median prostate weight and PSA density were equal to 45 grams and 0.21 vs. 63 grams and 0.15 in men with PCa vs. normal parenchyma, respectively. A normal parenchyma was diagnosed in the remaining 660/1032 (64%) men. The detection rate for overall cancers vs csPCa using SPBx vs. TPBx PIRADS > 3 vs. TPBx PIRADS > 4 was equal to 90.3 and 95.6% vs 72% and 83.8% vs 48.4 and 60.3%, respectively; in detail, SPBx missed 12 (4.5%) suggestive as being csPCa vs 44 (16.2%) and 108 (39.7%) missed by TPBx PI-RADS > 3 and TPBx PI-RADS > 4, respectively (18). The detection rate for csPCa performing cognitive transperineal fusion biopsy vs transrectal vs transperineal MRI/TRUS fusion biopsy was superimposable and equal to 35.8% (82/229) vs 35.5% (60/152) vs 36.5% (46/126), respectively (18); in detail, 40/228 (17.5%) csPCa were diagnosed in the anterior zone of the gland by transperineal targeted approach.
In definitive, in our series (18), mpMRI significantly reduced the number of unnecessary repeat prostate biopsies (about 50% of the cases using a PI-RADS score > 3); on the other hand, our results suggested that the patients should be informed of the significantly false-negative rate for csPCa of TPBx in the presence of PI-RADS > 3 (16.2%) or > 4 (39.7%).

Discussion

The improvement of diagnostic imaging by mpMRI has allowed to perform targeted biopsies of suspicious area increasing the accuracy in the diagnosis of csPCa (19) resulting predictive of definitive Gleason score with a higher detection rate of cancer for each core in comparison with standard prostate biopsy schemes. The detection rate for PCa of mpMRI is between 39% and 59% (20) with an incidence of cancer located only in the anterior zone

Figure 1. Transperineal stereotactic fusion prostate biopsy.

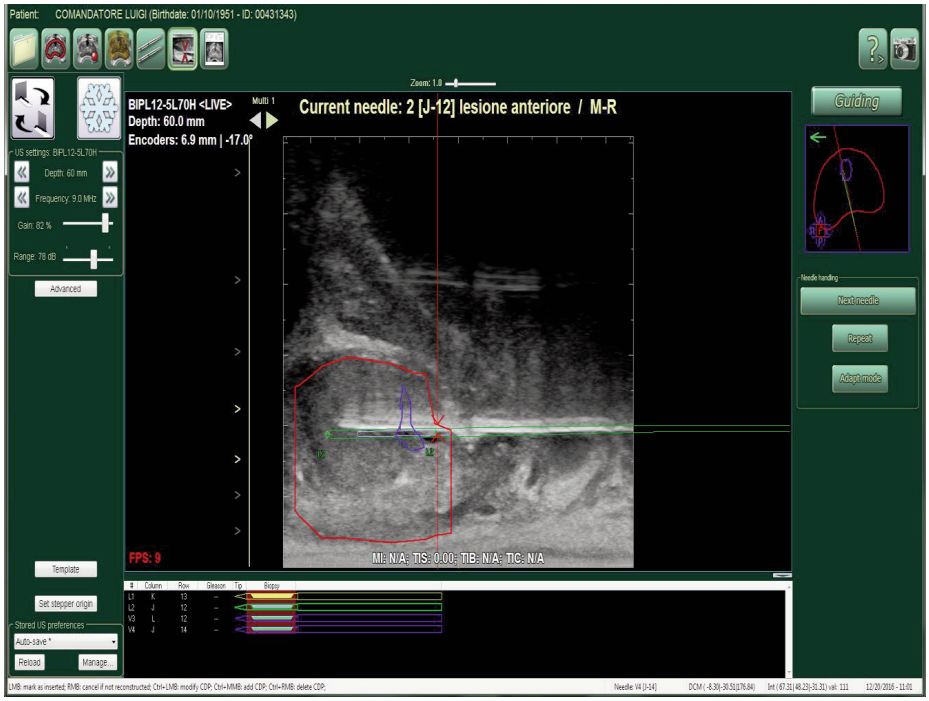

Figure 2. Report of stereotactic transperineal fusion targeted biopsy.

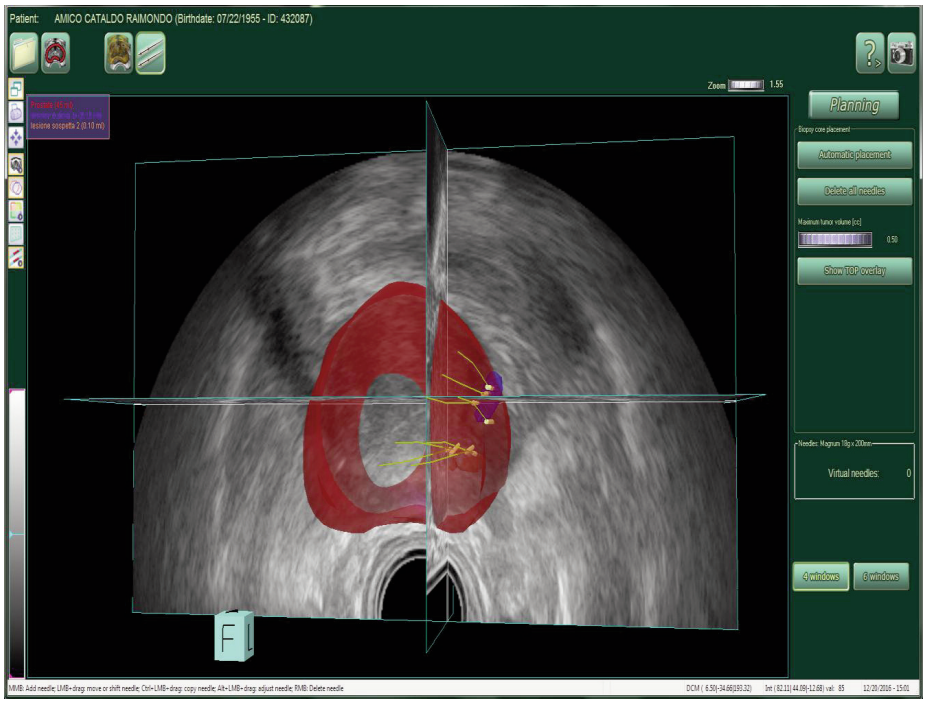

equal to 20% (21, 22). Although mpMRI is strongly recommended in men candidate to repeat biopsy or enrolled in AS protocols, still today, extended or SPBx should be always combined with mpMRI/TRUS fusion biopsy because the false negative rate of mpMRI (15-20% of PCa with low volume and Gleason score > 7) and the variable diagnostic accuracy reported using the different mpMRI/TRUS fusion biopsy platforms (18). The targeted biopsy of mpMRI suspicious areas could be performed using "in-bore" mpMRI-guidance, real-time mpMRI/TRUS imaging fusion or performing cognitive mpMRI/TRUS biopsies; although the detection rate for csPCa is superimposable performing cognitive vs fusion targeted biopsy (23), many papers have demonstrated a higher accuracy in favour of the fusion technique (24); in fact, the detection rate for csPCa is directly correlated with the expertise of the surgeon and the accuracy of the MRI/TRUS fusion platforms.

In addition, few data have been reported regarding the accuracy of transrectal vs transperineal mpMRI/TRUS fusion approach in diagnosing clinically significant PCa (12). In this respect, the two approaches are provided of a superimposable detection rate for PCa, but, at the same time, the transperineal approach allows to easily and better reach the anterior zone of the gland (16, 25) resetting the risk of sepsis (15, 26, 27). The estimated targeting error of transperineal stereotactic biopsies is below 1 millimeter (28); therefore, the higher accuracy in the diagnosis of csPCa using the template combined with stereotactic fusion platforms (**Figures 1, 2**) improve the accuracy in the reevaluation of men enrolled in Active Surveillance (29) protocols and/or the treatment and reevaluation of men enrolled in clinical trials and candidate to focal therapy (30).

Conclusions

Although mpMRI is mandatory in order to improve the accuracy of prostate biopsy in the diagnosis of csPCa, still today, the systematic biopsy should be performed, anyway, in addition to targeted cores (PIRADS score > 3) or alone (negative mpMRI) in the presence of clinical parameters suspicious for cancer; in this respect, the transperineal approach reset the risk of sepsis and improve the diagnosis of csPCa located in the anterior zone of the gland.

References

1. Loeb B, Carter HB, Berndt SI, et al. Complications after prostate biopsy: data from SEE-Medicare. J Urol. 2011; 186:1830-1844.

2. Pinkhasov GI, Lin YK, Palmerola R, et al. Complications following prostate needle biopsy requiring or emergency department visits- experience from 1000 consecutive cases. BJU Int. 2012; 110:369-374.

3. Ehdaie B, Vertosick E, Spaliviero M, et al. The impact of repeat biopsies on infectious complications in men with prostate cancer on active surveillance. J Urol. 2014; 191:660-664.

4. Schröder FH, Hugosson J, Roobol MJ, ERSPC Investigators. Prostate-cancer mortality at 11 years of follow-up. N Engl J Med. 2012; 366:981-990.

5. Pepe P, Garufi A, Priolo G, Pennisi M. Can 3 Tesla pelvic phase-array MRI avoid unnecessary repeat prostate biopsy in patients with PSA below 10 ng/ml? Clinical Genitourinary Cancer. 2015; 13:e27-30.

6. Roethke MC, Kuru TH, Schultze S, et al. Evaluation of the ESUR PI-RADS scoring system for multiparametric MRI of the prostate with targeted MR/TRUS fusion-guided biopsy at 3.0 Tesla. Eur Radiol. 2014; 24:344-352.

7. Pepe P, Garufi A, Priolo G, et al. Prostate cancer detection at repeat biopsy biopsy: can pelvic phased-array multiparametric MRI replace saturation biopsy? Anticancer Res. 2013; 33:1195-1199.

8. Hoeks CM, Somford DM, van Oort IM, et al. Value of 3-T multiparametric magnetic resonance imaging and magnetic resonance-guided biopsy for early risk restratification in active surveillance of low-risk prostate cancer: a prospective multicenter cohort study. Invest Radiol. 2014; 49:165-172.

9. Pepe P, Garufi A, Priolo G, Pennisi M. Can MRI/TRUS fusion targeted biopsy replace saturation prostate biopsy in the re-evaluation of men in active surveillance? World J Urol. 2016; 34:1249-1453.

10. Barrett T, Haider MA. The Emerging Role of MRI in Prostate Cancer Active Surveillance and Ongoing Challenges. AJR Am J Roentgenol. 2017; 208:131-139.

11. Westhoff N, Siegel FP, Hausmann D, et al. Precision of MRI/ultrasound-fusion biopsy in prostate cancer diagnosis: an ex vivo compari-

son of alternative biopsy techniques on prostate phantoms. World J Urol. 2017; 35:1015-1022.

12. Pepe P, Garufi A, Priolo G, Pennisi M. Transperineal Versus Transrectal MRI/TRUS Fusion Targeted Biopsy: Detection Rate of Clinically Significant Prostate Cancer. Clin Genitourin Cancer. 2017; 15:e33-e36.

13. Kongnyuy M, George AK, Rastinehad AR, Pinto PA. Magnetic Resonance Imaging-Ultrasound Fusion-Guided Prostate Biopsy: Review of Technology, Techniques, and Outcomes. Curr Urol Rep. 2016; 17(4):32.

14. Rastinehad AR, Abboud SF, George AK, et al. Reproducibility of Multiparametric MRI and Fusion-Guided Prostate Biopsy: Multi-Institutional External Validation by a Propensity Score Matched Cohort. J Urol. 2016; 195:1737-1783.

15. Pepe P, Aragona F. Morbidity following transperineal prostate biopsy in 3,000 patients submitted to 12 VS. 18 VS. more than 24 needle cores. Urology. 2013; 81:1142-1146.

16. Pepe P, Dibenedetto G, Pennisi M, et al. Detection rate of anterior prostate cancer in 226 patients submitted to initial and repeat transperineal biopsy. Urol Int. 2014; 93:189-192.

17. Epstein J, Walsh P, Carmichael M. Pathological and clinical findings to predict tumor extent of non palpable (stage T1c) prostate cancer. JAMA. 1994; 271:368-374.

18. Pepe P, Garufi A, Priolo GD, et al. Is it time to perform only MRI targeted biopsy? Our experience in 1032 men submitted to prostate biopsy. J Urol. 2018; 200:774-778.

19. Shoji S. Magnetic resonance imaging-transrectal ultrasound fusion image-guided prostate biopsy: Current status of the cancer detection and the prospects of tailor-made medicine of the prostate cancer. Investig Clin Urol. 2019; 60(1):4-13.

20. Fandella A, Scattoni V, Galosi A, et al. Italian prostate biopsies group. Anticancer Res. 2017; 37:413-424.

21. Filson CP, Natarajan S, Margolis DJ, et al. Prostate cancer detection with magnetic resonance-ultrasound fusion biopsy: The role of systematic and targeted biopsies. Cancer. 2016; 122:884-892.

22. Pepe P, Pennisi M. Prostate Cancer Diagnosis and Management Across Twenty Years of Clinical Practice: A Single-center Experience on 2,500 Cases. Anticancer Res. 2019; 39:1397-1401.

23. Wegelin O, Exterkate L, van der Leest M, et al. The FUTURE Trial: A Multicenter Randomised Controlled Trial on Target Biopsy Techniques Based on Magnetic Resonance Imaging in the Diagnosis of Prostate Cancer in Patients with Prior Negative Biopsies. Eur Urol. 2019; 75(4):582-590.

24. Cornud F, Roumiguié M, Barry de Longchamps N, et al. Precision Matters in MR Imaging-targeted Prostate Biopsies: Evidence from a Prospective Study of Cognitive and Elastic Fusion Registration Transrectal Biopsies. Radiology. 2018; 287(2):534-542.

25. Hansen N, Patruno G, Wadhwa K, et al. Magnetic Resonance and Ultrasound Image Fusion Supported Transperineal Prostate Biopsy Using the Ginsburg Protocol: Technique, Learning Points, and Biopsy Results. Eur Urol. 2016; 70:332-340.

26. Grummet J, Pepdjonovic L, Huang S, et al. Transperineal vs. transrectal biopsy in MRI targeting. Transl Androl Urol. 2017; 6:368-375.

27. Stefanova V, Buckley R, Flax S, et al. Transperineal Prostate Biopsies Using Local Anesthesia: Experience with 1,287 Patients. Prostate Cancer Detection Rate, Complications and Patient Tolerability. J Urol. 2019; 201(6):1121-1126.

28. Kuru TH, Roethke M, Popeneciu V, et al. Phantom study of a novel stereotactic prostate biopsy system integrating preinterventional magnetic resonance imaging and live ultrasonography fusion. J Endourol. 2012; 26:807-13.

29. Voss J, Pal R, Ahmed S, et al. Utility of early transperineal template-guided prostate biopsy for risk stratification in men undergoing active surveillance for prostate cancer. BJU Int. 2018; 121:863-870.

30. Mortezavi A, Krauter J, Gu DA, et al. Extensive histological sampling following focal therapy of clinically significant prostate cancer with high-intensity focused ultrasound. J Urol. 2019 May 1:101097JU0000000000000298. [Epub ahead of print]

Correspondence

Pietro Pepe, MD

Urology Unit - Cannizzaro Hospital, Via Messina 829, Catania, Italy

E-mail: piepepe@hotmail.com

Phone: + 39 957263285

Fax: + 39 957263259